

# Infected abdominal aneurysm due to *Salmonella species*

## *Aneurisma de aorta abdominal infectado por Salmonella species*

Marina Helena Fernandes de Aguiar Alioti<sup>1</sup>, Romeu Alioti<sup>2,3</sup>, Renato Campos Soares de Faria<sup>4</sup>, Otacílio de Camargo Júnior<sup>1</sup>, Martin Andreas Geiger<sup>1,5</sup>

### Abstract

Infected abdominal aortic aneurysms are rare and have high mortality due to sepsis and the possibility of rupture. The treatment of choice is open repair with aneurysm resection, debridement and reconstruction with an autologous vein graft. More recently, case series have been described in which the endovascular approach was the first option. With both approaches adjuvant antibiotic therapy is imperative. We report an illustrative case in which the treatment was open surgery reconstruction using an autologous vein graft.

**Keywords:** infected aneurysm; aortic aneurysm; micotic aneurysm.

### Resumo

Os aneurismas de aorta abdominal infecciosos (AAAs) são raros e apresentam uma alta mortalidade devido à septicemia e ao risco de ruptura. A opção terapêutica consagrada consiste na correção aberta com ressecção do aneurisma, debridamento e reconstrução com veia autóloga. Mais recentemente, alguns grupos vêm relatando séries de casos nas quais se realizou tratamento endovascular. Em ambas as opções, a antibioticoterapia adjuvante é imperativa. Relatamos um caso ilustrativo em que o tratamento de escolha foi a cirurgia aberta com reconstrução utilizando-se veia autóloga.

**Palavras-chave:** aneurisma infectado; aneurisma aórtico; aneurisma micótico.

<sup>1</sup> Hospital da Pontifícia Universidade Católica de Campinas – PUC-Campinas, Campinas, SP, Brazil.

<sup>2</sup> Santa Casa de Ribeirão Preto, Ribeirão Preto, SP, Brazil.

<sup>3</sup> Hospital Santa Lydia, Ribeirão Preto, SP, Brazil.

<sup>4</sup> Santa Casa de Ribeirão Preto, Instituto de Diagnóstico por Imagem – IDI, Ribeirão Preto, SP, Brazil.

<sup>5</sup> Universidade Estadual de Campinas – UNICAMP, Hospital de Clínicas – HC, Campinas, SP, Brazil.

Financial support: None.

Conflicts of interest: No conflicts of interest declared concerning the publication of this article.

Submitted: June 15, 2015. Accepted: December 09, 2015.

The study was carried out at Hospital da Pontifícia Universidade Católica de Campinas (PUC-Campinas), Campinas, SP, Brazil.

## INTRODUCTION

Abdominal aortic aneurysms (AAA) are the most common type that we see in our practice as vascular surgeons. One of the rarest types (1-18%) of AAA is the infected abdominal aortic aneurysm (IAAA), which is responsible for a high mortality rate (20%).<sup>1,2</sup> These aneurysms can form as the result of a preexisting infection or infection may be a secondary process. The infectious agents most often found in these aneurysms are *Salmonella sp* (40%) *Staphylococcus aureus* and *Streptococcus sp*.<sup>3,4</sup>

Among stable patients, a suspicion of this diagnosis may be raised because of a clinical presentation including abdominal or lumbar pains, weight loss, elevated erythrocyte sedimentation rate, positive blood culture, symptoms of urethral involvement or stenosis and imaging exams, such as computed tomography.<sup>5</sup>

Infected abdominal aortic aneurysms are generally refractory to antibiotic therapy if this is the only treatment. Due to the major risk of rupture and septicemia, the first option is open surgery with resection of the aneurysm and extensive debridement of the infected aorta. Other options are resection of the AAAI with extra-anatomic reconstruction or endovascular aneurysm repair.<sup>1,3,5</sup> We describe the case of a patient with a diagnosis of AAAI due to *Salmonella sp* who was successfully treated with a venous graft using the femoral vein from the left lower limb.

## CASE REPORT

A 65-year-old patient was admitted to hospital by the general surgery service after presenting with intense abdominal pains, primarily in the area of the

left flank and left iliac fossa. The patient's medical history included hypertension, dyslipidemia and diverticular disease that was not being managed. On physical examination, general appearance was regular, but the patient was febrile and complained of pain on abdominal palpation, but was free from signs of peritonitis.

Laboratory test results were as follows, hemoglobin: 10.8 g/dL, leukocytosis: 27,510/mm<sup>3</sup>, with 18% basophils; fasting glycemia: 43.6 mg/dL; potassium: 3.1; amylase: 56.6U/L; renal function was normal; and urinalysis showed 18 leukocytes per field and was negative for nitrite. A blood culture was positive for hard to grow gram positive cocci.

A computed tomography scan was performed because of the intense abdominal pains, revealing an abdominal aortic aneurysm with signs suggestive of infection (Figure 1). Antibiotic treatment was initiated (clindamycin and ceftriaxone) and a vascular surgery assessment was requested.

Eight days after admission, the patient underwent open surgery to repair the aneurysm. First the deep femoral vein of the left lower limb was resected and prepared and then the aorta was identified and isolated via laparotomy. After proximal and distal ligation, the aneurysm sac was resected and the vein anastomosed proximally to the aorta wall and distally to the right and left common iliacs, since the patient's deep femoral vein had a duplicated segment running to a confluence, becoming single, so the result was a bifurcated graft. Material was sent to be cultured and the result was positive for *Salmonella sp* growth (Figure 2).

The patient was transferred to the intensive care unit (ICU), where he remained for 8 days. After 3 days he

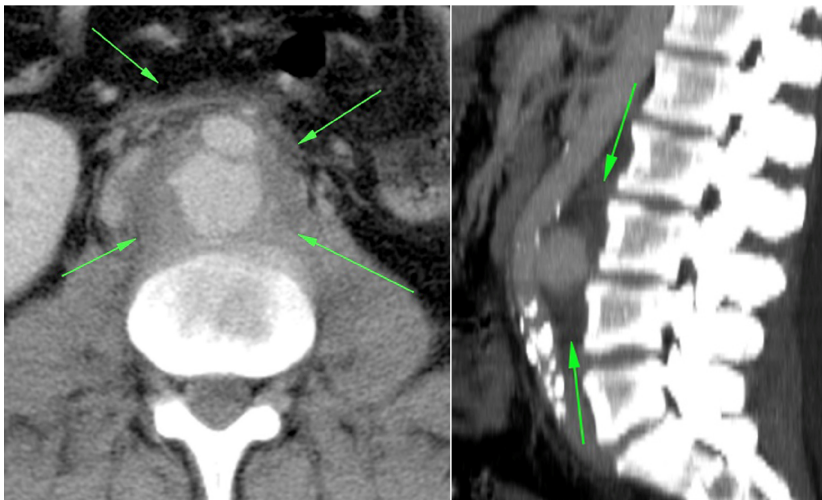

Figure 1. Computed tomography showing an abdominal aortic aneurysm with signs suggestive of infection.

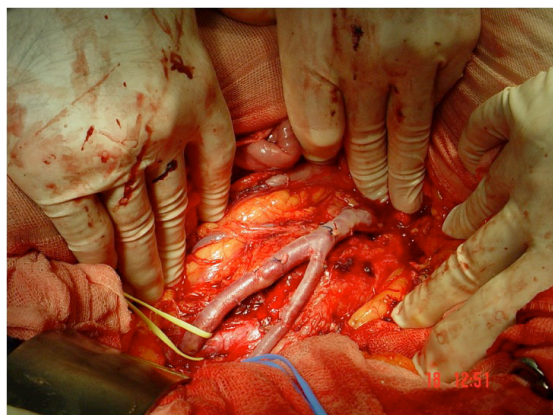


Figure 2. Proximal anastomosis of the vein to the aorta wall and distally to the left and right common iliacs.

exhibited clinical deterioration, with fever, peritonitis and pneumonia. The case was discussed with the infectology service, which recommended withdrawal of the clindamycin and introduction of oxacillin. The patient was discharged 23 days after repair of the aneurysm and was put on oral antibiotic therapy for 6 months (ciprofloxacin) (Figure 3).

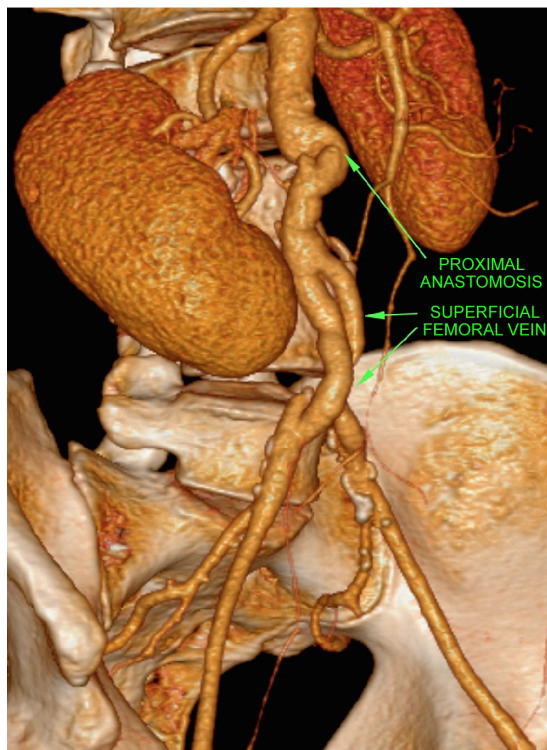


Figure 3. Control computed tomography showing patent graft.

## DISCUSSION

In 1885, Osler was the first person to use the term mycotic aneurysm to describe an aneurysm caused by bacterial endocarditis. Nowadays, the most appropriate name is infected aneurysm, which encompasses both those that are the result of a prior infection and those that were already present and became infected as a secondary process.<sup>6</sup>

Infected abdominal aortic aneurysms are rare and have a mortality rate of around 20%.<sup>5</sup> As the years have gone by and several different teams have accumulated experience with the condition, treatment based solely on antibiotics has been shown to be inconsistent when compared with a combination of surgical treatment and antibiotics, with mortality rates as high as 96% reported in the literature.<sup>7</sup>

The preferred treatment, once a diagnosis has been made, consists of antibiotic therapy, extensive debridement of infected tissues and reconstruction with in situ or extra-anatomical grafts, depending on the severity of the infection.<sup>1,3,5</sup> Grafts can be constructed using autologous vessels or prostheses. Veins are more resistant to infection and exhibit a lower risk of reinfection (1.7% in revascularizations with veins vs. 12.3% in revascularizations with prostheses).<sup>6</sup> The choice of the autologous deep vein is based on the fact that it is less likely to degenerate and also because it is more compatible with the size

of the aortoiliac segment. The great saphenous vein is more susceptible to focal stenoses and thromboses caused by progressive myointimal hyperplasia, which reaches rates of up to 24%.<sup>6,8,9</sup> Dorweiler et al. report an 87% patency rate, a limb salvage rate of 93% and primary patency of 81% over 5 years.<sup>10</sup>

In 2010, Kan et al.<sup>11</sup> analyzed 48 patients treated using endovascular techniques, reporting mortality of 10% at 30 days and 15% over medium-term follow-up. Encouraged by the good results reported by several authors, the endovascular approach has begun to be more widely employed, primarily in patients with multiple comorbidities and short life expectancy.<sup>2,12,13</sup> However, many authors believe that survivors should still undergo open repair to resect the infected aorta, since the contents of the infected aneurysm sac could be responsible for relapses.<sup>12</sup>

Percutaneous drainage of the aneurysm sac after endovascular repair has been proposed, with the aim of reducing the infectious content of the sac.<sup>14</sup> However, what many authors describe in practice is that complete drainage is technically difficult, and that surgical debridement is still the best solution.<sup>15</sup>

The choice of antibiotics and the duration of treatment after surgical resection will be determined on the basis of the patient's parameters and test results. It is recommended that follow-up include

tests of inflammatory indicators, such as C-reactive protein and white blood cell counts.<sup>12</sup> Services that use endovascular treatment as the first-line treatment choose lifelong antibiotic therapy.<sup>16</sup>

Despite the existence of controversies, endovascular treatment is now being used to repair infected aneurysms, primarily in high-risk patients.<sup>15,16</sup> However, if the conditions of both the surgical team and the patient allow, we believe that open repair with an autologous graft offers patients the possibility of a complete cure, with less likelihood of relapse when antibiotic therapy is withdrawn.

## ■ REFERENCES

- Fukunaga N, Hashimoto T, Ozu Y, Yuzaki M, Shomura Y, Fujiwara H, et al. Successful treatment for infected aortic aneurysm using endovascular aneurysm repairs as a bridge to delayed open surgery. *Ann Vasc Surg.* 2012;26(2):280-e5-280-e8.
- Sedivy P, Spacek M, El Samman K, et al. Endovascular treatment of infected aortic aneurysms. *Eur J Vasc Endovasc Surg.* 2012;44(4):385-94. <http://dx.doi.org/10.1016/j.ejvs.2012.07.011>. PMID:22917674.
- Aerts PD, van Zitteren M, Kotsopoulos AM, van Berge Henegouwen DP, Vriens PW, Heyligers JM. Infected abdominal aneurysm due to Salmonella sepsis: report of a unique case treated using the superficial femoral vein. *Ann Vasc Surg.* 2012;26(2):279-e5-279-e7.
- Brossier J, Lesprit P, Marzelle J, Allaire E, Becquemin JP, Desgranges P. New bacteriological patterns in primary infected aorto-iliac aneurysms: a single-centre experience. *Eur J Vasc Endovasc Surg.* 2010;40(5):582-8. <http://dx.doi.org/10.1016/j.ejvs.2010.07.020>. PMID:20843713.
- Gibbons CP. What is the best treatment for primary infected aortic aneurysms? *Eur J Vasc Endovasc Surg.* 2011;42(5):625-6. <http://dx.doi.org/10.1016/j.ejvs.2011.08.002>. PMID:21855371.
- Brito CJD. *Cirurgia vascular: cirurgia endovascular, angiologia.* 3. ed. Rio de Janeiro: Revinter; 2014.
- Soravia-Dunand VA, Loo VG, Salit IE. Aortitis due to Salmonella: report of 10 cases and comprehensive review of the literature. *Clin Infect Dis.* 1999;29(4):862-8. <http://dx.doi.org/10.1086/520450>. PMID:10589904.
- Cardozo MA, Frankini AD, Bonamico TP. Use of superficial femoral vein in the treatment of infected aortoiliac prosthetic grafts. *Cardiovasc Surg.* 2002;10(4):304-10. [http://dx.doi.org/10.1016/S0967-2109\(02\)00024-8](http://dx.doi.org/10.1016/S0967-2109(02)00024-8). PMID:12359398.
- Dirven M, van der Jagt MF, Barendregt WB, van der Vliet D. The Efficacy of Autologous Femoropopliteal Vein Reconstruction for Primary Aortic and Aortic Graft Infection. *Ann Vasc Surg.* 2015;29(6):1188-95. <http://dx.doi.org/10.1016/j.avsg.2015.03.043>. PMID:26009479.
- Dorweiler B, Neufang A, Chaban R, Reinstadler J, Duenschede F, Vahl CF. Use and durability of femoral vein for autologous reconstruction with infection of the aortoiliac axis. *J Vasc Surg.* 2014;59(3):675-83. <http://dx.doi.org/10.1016/j.jvs.2013.09.029>. PMID:24342063.
- Kan CD, Lee HL, Luo CY, Yang YJ. The efficacy of aortic stent grafts in the management of mycotic abdominal aortic aneurysm-institute case management with systemic literature comparison. *Ann Vasc Surg.* 2010;24(4):433-40. <http://dx.doi.org/10.1016/j.avsg.2009.08.004>. PMID:19932948.
- Yu SY, Lee CH, Hsieh HC, Chou AH, Ko PJ. Treatment of primary infected aortic aneurysm without aortic resection. *J Vasc Surg.* 2012;56(4):943-50. <http://dx.doi.org/10.1016/j.jvs.2012.03.018>. PMID:22608792.
- Setacci C, de Donato G, Setacci F. Endografts for the treatment of aortic infection. *Semin Vasc Surg.* 2011;24(4):242-9. <http://dx.doi.org/10.1053/j.semvascsurg.2011.10.009>. PMID:22230680.
- Pryluck DS, Kovacs S, Maldonado TS, et al. Percutaneous drainage of aortic aneurysm sac abscesses following endovascular aneurysm repair. *Vasc Endovascular Surg.* 2010;44(8):701-7. <http://dx.doi.org/10.1177/1538574410376451>. PMID:20675322.
- Silverberg D, Halak M, Yakubovitch D, et al. Endovascular management of mycotic aortic aneurysms. *Vasc Endovascular Surg.* 2010;44(8):693-6. <http://dx.doi.org/10.1177/1538574410377667>. PMID:20675323.
- Jia X, Dong YF, Liu XP, Xiong J, Zhang HP, Guo W. Open and endovascular repair of primary mycotic aortic aneurysms: a 10-year single-center experience. *J Endovasc Ther.* 2013;20(3):305-10. <http://dx.doi.org/10.1583/13-4222MR.1>. PMID:23731302.

### Correspondence

Marina Helena Fernandes de Aguiar Alioti  
Hospital da Pontifícia Universidade Católica de Campinas – PUC-Campinas  
Av. John Boyd Dunlop, s/n - Jd. Ipaussurama  
CEP 13060-904 - Campinas (SP), Brazil  
E-mail: ma\_alioti@yahoo.com.br

### Author information

MHFAA - Resident of Vascular Surgery, Hospital da Pontifícia Universidade Católica de Campinas (PUC-Campinas).  
RA - Vascular surgeon, Santa Casa de Ribeirão Preto and Hospital Santa Lydia.  
RCSF - Chief radiologist, Departamento de Diagnóstico em Vascular, Instituto de Diagnóstico por Imagem (IDI), Santa Casa de Ribeirão Preto.  
OCJ - Vascular surgeon and chief of staff at Hospital da Pontifícia Universidade Católica de Campinas (PUC-Campinas).  
MAG - Vascular surgeon at Hospital de Clínicas da Universidade Estadual de Campinas (HC-UNICAMP) and Hospital da Pontifícia Universidade Católica de Campinas (PUC-Campinas).

### Author contributions

Conception and design: MHFAA, MAG  
Analysis and interpretation: MHFAA, RA, RCSF, OCJ, MAG  
Data collection: MHFAA, RA, RCSF  
Writing the article: MHFAA, MAG  
Critical revision of the article: MHFAA, RA, RCSF, MAG  
Final approval of the article\*: MHFAA, RA, RCSF, OCJ, MAG  
Statistical analysis: N/A.  
Overall responsibility: MHFAA, MAG

\*All authors have read and approved of the final version of the article submitted to *J Vasc Bras.*