

Percutaneous transhepatic venous access for hemodialysis: an alternative route for patients with end-stage renal failure

Acesso venoso trans-hepático percutâneo para hemodiálise: uma alternativa para pacientes portadores de insuficiência renal crônica

Joaquim Maurício da Motta-Leal-Filho¹, Francisco Cesar Carnevale², Felipe Nasser¹, Wilson de Oliveira Sousa Junior¹, Charles Edouard Zurstrassen¹, Airton Mota Moreira¹, Breno Boueri Affonso¹, Giovanni Guido Cerrí³

Abstract

Background: Percutaneous transhepatic venous access is an option for hemodialysis patients who have exhausted all traditional sites of venous access. **Objectives:** To present a small sample regarding the possibility and the functionality of transhepatic implantation of long-term catheters for hemodialysis in patients with no other possible access routes.

Methods: Retrospective observational analysis was made of the charts of six patients in which nine tunneled dialysis catheters were implanted by the percutaneous transhepatic route. Transhepatic catheters were placed in the absence of an available peripheral venous site. Patients were monitored to evaluate technical success, the complication rate, the infection rate and the duration of catheter patency.

Results: Four men and two women aged 31 to 85 years (mean age: 55 years). Technical success was 100%. The mean duration of catheter function was 300.5 days (range: 2 to 814 days). Means of primary and secondary patency were 179.60 and 328.33 days, respectively. The catheter thrombosis rate was 0.05 per 100 catheter-days as the infection rate. There were three early complications (within the first 30 days of catheter implantation): two catheter displacement and one infection. Two late complications were observed: one thrombosis and one migration. Three patients (50%) needed to have their catheters changed. The 30-day mortality rate was 33% but with no relation to the procedure.

Conclusion: It may be suggested that this technique is safe, however transhepatic hemodialysis catheters may be used in patients with no other options for deep venous access for hemodialysis, albeit as a last resort access route.

Keywords: Catheters, indwelling; Catheterization, central venous; Dialysis; Radiology, interventional; Liver circulation.

Resumo

Contexto: Acesso venoso trans-hepático percutâneo para hemodiálise é uma opção para pacientes que já exauriram acessos venosos tradicionais.

Objetivo: Apresentar uma série de casos que demonstram a factibilidade e a funcionalidade da implantação dos cateteres semi-implantáveis por meio de acesso venoso trans-hepático percutâneo em pacientes sem possibilidades de outros acessos.

Métodos: Análise observacional retrospectiva dos prontuários de seis pacientes que foram submetidos à implantação de nove cateteres trans-hepáticos percutâneos para hemodiálise. Os cateteres foram implantados na ausência de acessos venosos periféricos disponíveis. No seguimento dos pacientes, procurou-se avaliar: sucesso técnico do procedimento, taxa de complicação, taxa de infecção e patência do acesso.

Resultados: Quatro homens e duas mulheres com idades entre 31 e 85 anos (média: 55 anos). Sucesso técnico obtido em 100%. A média de duração dos cateteres foi de 300,5 dias (2 a 814 dias). Médias de patência primária e secundária foram de 179,60 e 328,33 dias, respectivamente. Taxa de trombose dos cateteres foi de 0,05 por 100 cateteres-dias, assim como a taxa de infecção. Houve três complicações precoces (30 primeiros dias de implantação dos cateteres): dois deslocamentos dos cateteres e uma infecção. Duas complicações tardias foram observadas: uma trombose e uma migração. Três pacientes (50%) tiveram que trocar seus cateteres. Taxa de mortalidade em 30 dias foi de 33%, porém não relacionada ao procedimento.

Conclusão: Implantação do cateter para hemodiálise por meio do acesso venoso trans-hepático percutâneo parece ser uma técnica segura, porém a utilização desse acesso deve ser aplicada somente em casos de esgotamento de outros acessos vasculares profundos.

Palavras-chave: Cateteres de demora; Cateterismo venoso central; Diálise; Radiologia intervencionista; Circulação hepática.

Study carried out at the Service of Interventional Radiology of Clinics Hospital of Faculdade de Medicina da Universidade de São Paulo (HC-FMUSP), São Paulo (SP), Brazil.

¹ Members of the Brazilian Society of Interventional Radiology and Endovascular Surgery (SoBrice); Referring physicians at the Service of Interventional Radiology of Radiology Institute (InRad), Heart Institute of the Clinics Hospital of Faculdade de Medicina da Universidade de São Paulo (HC-FMUSP), and São Paulo Cancer Institute (ICESP), São Paulo (SP), Brazil.

² Member of SoBRICE and Head of the Service of Interventional Radiology of InRad, Heart Institute of HC-FMUSP, and ICESP, São Paulo (SP), Brazil.

³ Member of the Brazilian College of Radiology (CBR) and Head of the department of radiology of InRad of HC-FMUSP and of ICESP, São Paulo (SP), Brazil.

No conflict of interest was declared concerning the publication of this article.

Received on Apr 20, 2010. Accepted on Jun 28, 2010

J Vasc Bras. 2010;9(3):131-136.

Introduction

The number of patients with chronic renal failure (CRF) in need of dialysis has been increasing over the world each year. In the United States, in 2003, over 200 thousand patients were undergoing hemodialysis – the annual growth rate is estimated in 6%¹. There are two access methods for hemodialysis in the chronic renal patient: through catheters or arteriovenous fistula (AVF). The National Kidney Foundation – Dialysis Outcomes Quality Initiative (NKF-DOQI) recommends that 10% of the patients on hemodialysis use long-term catheters, which are especially indicated for cases in which all possibilities of dialysis through AVF have been exhausted^{2,3}.

The central venous access chosen for long-term catheters is the internal jugular vein due to its technical easiness, besides the fact that it presents lower rates of complications⁴⁻⁸. However, it is known that, due to multiple catheter exchanges and manipulations, these veins may occlude. When it is not possible to use the internal jugular vein, other accesses may be explored, such as the subclavian and femoral veins and the inferior vena cava via translumbar or transhepatic approaches^{1,3,5,9-12}.

Traditionally, the deep venous access for catheter insertion used to be obtained by surgical procedure. The first deep venous catheter insertion via percutaneous endovascular approach was performed in 1989¹³. The percutaneous transhepatic access was initially described for the administration of parenteral nutrition⁹, but in 1994 Po et al. reported a case in which this same access was used for hemodialysis¹⁴. Since then, many descriptions of this technique with this objective have been found in the literature (case reports and small case series) as an option for patients with no other available deep venous access^{1,3,5,10,11}. This is a feasible procedure which presents rates of complication and infection similar to those of usual venous approaches, besides demonstrating long-lasting patency. In the present paper, we report a case series of transhepatic long-term catheter insertions for hemodialysis in patients without other access available for this purpose. Technical success, number of complications, rate of infection and duration of catheter patency were evaluated at patients' follow-up.

Methods

Patients

This is a retrospective and observational study carried out through analysis of medical records from

December 2005 to February 2008, in which six patients who received nine long-term catheter implants via percutaneous transhepatic approach were enrolled. All patients were on hemodialysis and did not have other temporary or definitive (AVF) venous accesses available, which was confirmed by duplex scan, hence the option was the transhepatic implant PermCath. Assessment of hepatic veins' patency was made by duplex scan. We adopted the standard recommendations for deep venous access by the Society of Interventional Radiology (SIR)⁴.

Technique

Platelet count less than 50,000, Partial Prothrombin Time (INR) >1.5, voluminous ascites, ongoing infection or sepsis were contra-indications for catheter insertion.

The insertion of the first catheters was performed by a team of anesthetists with the patient under cardiorespiratory monitoring and general anesthesia with propofol, midazolane, fentanyl, intravenous atracurium and inhalant sevoflurane. The secondary procedures, exchange or removal of catheters were made with 2% lidocaine local anesthesia. Asepsis and antisepsis were made in the upper abdominal quadrant and right hemithorax with Polyvinyl pyrrolidone alcohol-iodine (PVP-I), and 1.0g of intravenous cefazolin was administered as antibiotic prophylaxis. Under direct fluoroscopy, the liver was punctured with the kit NPAS-100 (Cook[®]), 21-gauge Chiba needle (15 cm) on the tenth right intercostal space in the mid-axillary line, aiming at reaching the right hepatic vein (RHV) (Figures 1 and 2). The RHV was accessed by the Chiba needle and confirmed by contrast injection. A 0.018" guide wire was inserted through a needle and placed on the inferior vena cava (IVC). A coaxial catheter was then placed over the 0.018" guide wire, and the latter was replaced by a stiff 0.035" guide wire (Amplatz, 260 cm, J tip, Cook[®]) and positioned in the right atrium. The transhepatic route was dilated and a peel-away sheath (PermCath[®]) was inserted. A subcutaneous tunnel was made over the mid-axillary line (Figures 3 and 4). The distal tip of the long-term catheter was then placed in the caval-atrial junction transition and sutured to the skin (Figure 5). After testing the catheter, it was heparinized with 20mL of a solution containing 250mL of 0.9% normal saline and 5,000 UI sodium heparin.

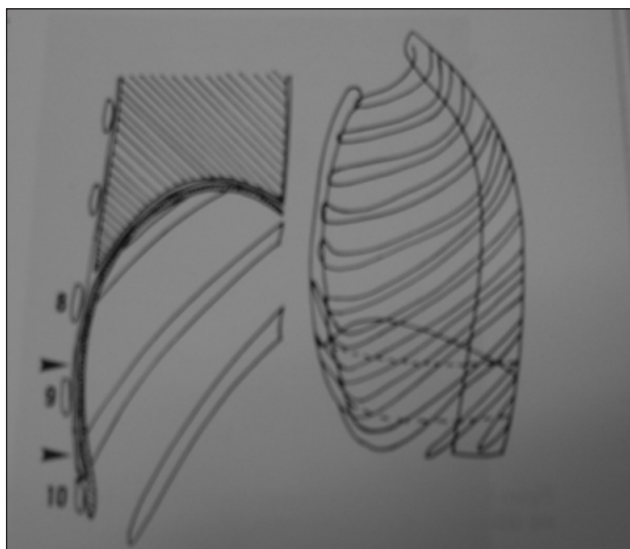


Figure 1 – Puncture: 9th or 10th right intercostal spaces in the mid-axillary line.

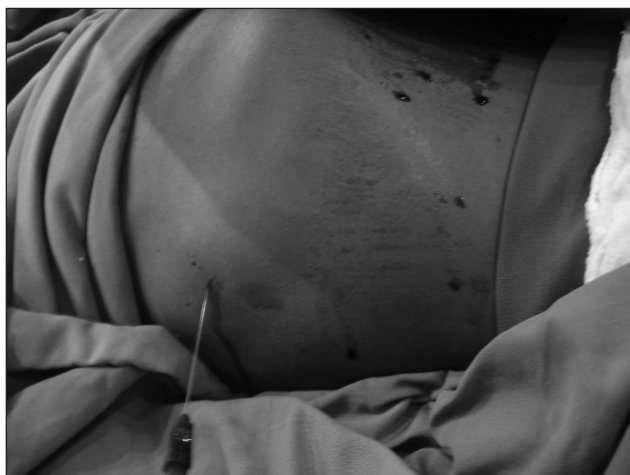

Figure 2 – Puncture of skin with Chiba needle in the intercostal space previously chosen.

Results

This study enrolled four male and two female patients aging from 31 to 85 years old (mean of 55 years old) (Table 1). Nine catheters were inserted in six patients, and three of them had their access sites changed once. The technical success was obtained in 100% of the sample (nine catheters in nine patients). There were no complications within the first 24 hours of the procedure. The total time of percutaneous transhepatic implantation was of 1,803 catheter-days, mean of 300.5 (minimum of 2 days; maximum of 814 days).

Five long-term catheters (Medcomp[®], Harleyville, Pa) measuring 36 cm were inserted in four patients, and four



Figure 3 – Catheterization of the right hepatic vein and confection of subcutaneous tunnel in the mid-axillary line.

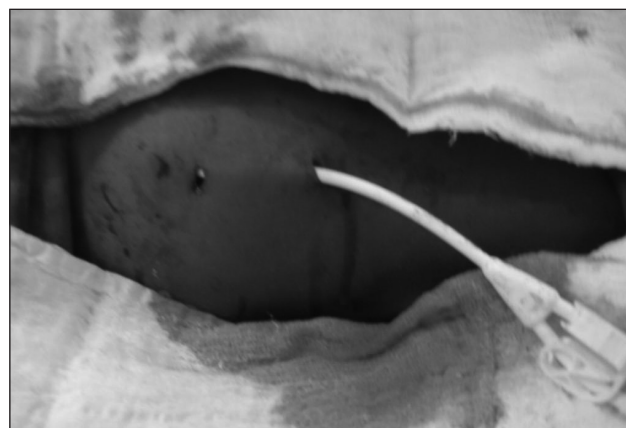


Figure 4 – Final external aspect.

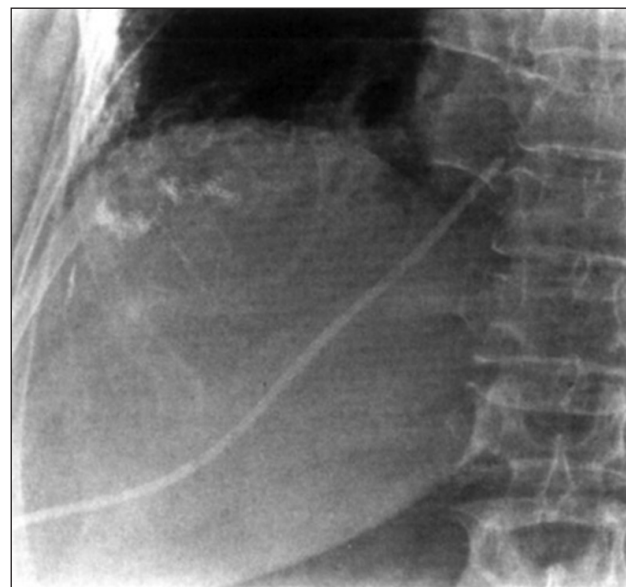


Figure 5 – Final radiologic aspect showing the catheter in the right position.

Table 1 – Demographic data

Case	Sex	Age	PermCath length (cm)	Primary patency	Secondary patency	Complications			Death
						I	T	M	
1	Male	31	45	814	-	-	-	-	No
2	Male	85	45 45	106	687	-	x	-	Yes
3	Male	68	36	2	-	-	-	-	Yes
4	Male	37	36	2	-	-	-	-	Yes
5	Female	46	36 45	128	146	-	-	x	No
6	Female	63	36 36	26	152	x	-	-	No

Age in years; patency in days.
I: infection; T: thrombosis; M: migration.

Table 2 - Complications

Complication characteristics	Type	Number of cases
Immediate complications (<24h)	-	-
Early complications (>24h and <30 days)	Catheter dislodgment	2
	Infection	1
Late complications (>30 days)	Thrombosis	1
	Migration	1

45-cm catheters (Quinton Instrument Co., Seattle, USA) in other three patients (Table 1). There were three cases of early complications (before the 30 first days with the implant) and two late complications (Table 2). One catheter had to be exchanged due to thrombosis of the false lumen 106 days after the procedure (case 2). In this study, the rate of catheter thrombosis was 0.05 per 100 catheter-days. One catheter had to be removed due to an infection of the subcutaneous tunnel 26 days after its insertion, being reinserted in the same RHV after a new puncture 42 days later (case 6). This patient presented with an abscess in the subcutaneous tunnel, leucopenia and positive culture for coagulase-negative *Staphylococci* at the catheter tip, but negative hemoculture. She was treated with vancomycin. This patient had a 15mL/min creatinine clearance after kidney transplantation and could wait 42 days until the new transhepatic catheter was reinserted for dialysis. In this study, the rate of infection was 0.05 per 100 catheter-days. One catheter dislodged and its distal tip was positioned inside the RHV, which caused it to lose its function and to be exchanged 128 days after the initial procedure (case 5). Two catheters required replacement seven and five days after their insertion due to dislodgement into the IVC and penetration into the atrial wall, respectively,

resulting in low dialysis flow (cases 2 and 5). Two patients died two days after the catheter insertion of infections not related to the procedure (cases 3 and 4). Another patient died 687 days after the first catheter insertion, also from causes not related to the procedure (case 2). In all three cases, the long-term catheters were functioning at the time of death.

The mean primary and secondary patencies were 179.66 days (minimum of 2 days and maximum of 814 days) and 328.33 days, respectively (Table 1).

Discussion

The best treatment for patients suffering from CRF is renal transplantation. Unfortunately, the annual increase rate of transplanted patients does not increase in the same proportion of the rate of patients who develop CRF, thus remaining the option of hemodialysis by means of AVF and semi-implantable long-term catheters, and peritoneal dialysis. Although the long-term catheter is not the best alternative while the patients wait for renal transplantation, for some patients it is the only – and sometimes definitive – option.

The internal jugular vein is the best temporary access for insertion of long-term catheters, and its benefits in relation to other access sites have already been shown and recommended^{2,4}, in addition to preserving the veins of the upper and lower limbs for subsequent AVF creation. These veins present low complication rates (stenosis/thrombosis) that may reach a maximum of 10%, while the subclavian veins account for a rate up to 50%^{15,16}. After exhausting all possibilities of venous access in the jugular, subclavian and femoral veins, preferentially in this order, the next access to be explored is the one agreed between the medical team and the patients and their relatives.

The long-term percutaneous transhepatic catheter insertion has been described as an exception approach for hemodialysis in patients who do not have any other conventional access site available^{1,3,5,10,11}. It is believed that the demand for alternative venous accesses will increase according to the increasing number of patients in need of hemodialysis. The most used hepatic veins are the RHD and the medium-sized hepatic vein. The RHD is preferable because it is peripheral (closer to the percutaneous puncture site), has a larger pathway and possesses a horizontal superior portion towards the IVC. It is believed that placing the catheter in this position may decrease the possibility of dislodgment and migration¹. In this study, the RHD was chosen in all cases.

Patients with coagulopathy and infection must be treated previously. Ascites can make the procedure difficult due to the intestinal loop interposition between the liver and the abdominal wall, to bleeding from the hepatic capsule, which is constantly in contact with the ascitic fluid, to catheter infection and dislodgment.

We achieved technical success in all patients, and no death was related to the procedure. The complication, infection and thrombosis rates were acceptable in comparison to those of other approaches⁶⁻⁸. The infection rate was of 0.05 per 100 catheter-days, and thrombosis rate was of 0.05 per 100 catheter-days, similar to those of other studies that used many types of venous access such as the internal jugular vein, the femoral vein and the translumbar access⁶⁻⁸. In this study, the primary patency was not impaired, which is intimately related to the thrombosis rate (mean of 179.60 days)¹. A mean of 300.5 days of a functioning catheter was obtained, a duration time higher than those found by Biswal et al., who obtained a mean of 250 days for PermCaths inserted via translumbar approach¹⁷. However, the maintenance of these accesses seems to be a challenge, because two catheters dislodged and required replacement. Another one migrated completely out of the deep venous system and had to be exchanged (33% of dislodgment/migration). It is believed that the respiratory movements are responsible for such events, for they lead the motion of the catheter, between the liver and the thoracic wall. Because of that, during the hemodialysis sessions, the adequate functioning of the catheter must be observed and, at the slightest sign of poor flow, it should be reviewed to diagnose a possible migration.

Catheter removal may be necessary mainly due to infections related to the long-term catheter, bleeding, fistulas and the discontinuation of hemodialysis in transplanted patients. It has been suggested that, when the catheter is

removed, its path should be embolized^{11,18}. In this series, a catheter had to be removed due to infection (case 6) and we opted for embolization of the path with Gelfoam, a temporary embolization agent, thus preserving the access for future use.

This study presents limitations because it was observational, retrospective, with a small sample, and without comparisons to catheters inserted through other access sites. Two patients died two days after the catheter insertion, thus restricting the follow-up to four patients.

Conclusion

One may suggest that this is a safe technique with low complication rates that can be used in patients without other deep venous accesses available for hemodialysis. It should be considered as an exception access though. Nevertheless, this case series, added to other studies, intends to bring up a discussion on the advantages and disadvantages of this peculiar approach.

References

1. Stavropoulos SW, Pan JJ, Clark TWI, et al. Percutaneous transhepatic venous access for hemodialysis. *J Vasc Interv Radiol.* 2003;14:1187-90.
2. National Kidney Foundation. NKF-DOQI clinical practice guidelines for vascular access, 2000. *Am J Kidney Dis.* 2001;37(suppl 1):S137-S181.
3. Smith TP, Ryan JM, Reddan DN. Transhepatic catheter access for hemodialysis. *Radiology.* 2004;232:246-51.
4. Silberzweig JE, Sacks D, Khorsandi AS, et al. Reporting standards for central venous access. *J Vasc Interv Radiol.* 2000;11:391-400.
5. Nasser F, Biagioni RB, Campos RCA, et al. Relato de caso: implante transparietohepático de cateter de longa permanência para diálise. *J Vasc Bras.* 2007;6:391-4.
6. Ewing F, Patel D, Petherick A, et al. Radiological placement of the AshSplit haemodialysis catheter: a prospective analysis of outcome and complications. *Nephrol Dial Transplant.* 2002;17:614-9.
7. Wivell W, Bettmann MA, Baxter B, et al. Outcomes and performance of the Tesio twin catheter system placed for hemodialysis access. *Radiology.* 2001;221:697-703.
8. Chow KM, Szeto CC, Leung CB, et al. Cuffed-tunnelled femoral catheter for long-term hemodialysis. *Int J Artif Organs.* 2001;24:443-6.
9. Azizkhan GR, Taylor LA, Jaques PF, et al. Percutaneous translumbar and transhepatic inferior vena caval catheters for prolonged vascular access in children. *J Pediatr Surg.* 1992;27:165-9.
10. Rosa-Diez GJ, Lambertini RG, Peralta O, et al. Transhepatic venous access as an alternative for Tesio catheter in the case of a patient on haemodialysis with antiphospholipid syndrome. *Nephrol Dial Transplant.* 2006;21:2031-3.

11. Bergey EA, Kaye RD, Reyes J, et al. Transhepatic insertion of vascular dialysis catheters in children: a safe, life-prolonging procedure. *Pediatr Radiol.* 1999;29:42-5.
12. Rodriguez-Cruz E, Bonilla M, Perez J. Percutaneous translumbar inferior vena cava catheter placement for long-term hemodialysis treatment. *Pediatr Nephrol.* 2007; 22:612-5.
13. Robertson LJ, Mauro MA, Jaques PF. Radiologic placement of Hickman catheters. *Radiology.* 1989;170:1007-9.
14. Po CL, Koolpe HA, Allen S, et al. Transhepatic PermCath for hemodialysis. *Am J Kidney Dis.* 1994; 24:590-1.
15. Schillinger F, Schillinger D, Montagnac R, et al. Post catheterization vein stenosis in haemodialysis: comparative angiographic study of 50 subclavian and 50 internal jugular accesses. *Nephrol Dial Transplant.* 1991;6:722-4.
16. Cimochoowski GE, Worley E, Rutherford WE, et al. Superiority of the internal jugular over the subclavian access for temporary dialysis. *Nephron.* 1990;54:154-61.
17. Biswal R, Noshier JL, Siegel RL, et al. Translumbar placement of paired hemodialysis catheters (Tesio catheters) and follow-up in 10 patients. *Cardiovasc Interv Radiol.* 2000;23:75-8.
18. Putnam SG 3rd, Ball D, Cohen GS. Transhepatic dialysis catheter tract embolization to close a venous-biliary-peritoneal fistula. *J Vasc Interv Radiol.* 1998;9:149-51.

Correspondence:

Joaquim Maurício da Motta Leal Filho
 Radiology Institute (InRad)
 Avenida Dr. Enéas de Carvalho Aguiar, 255, 3º andar – Cerqueira Cesar
 CEP: 05403-001 – São Paulo (SP), Brazil
 E-mail: jotamauf@yahoo.com.br

Authors' contributions

Study conception and design: JMMLF, FN and FCC
 Data analysis and interpretation: JMMLF, FCC and FN
 Data collection: JMMLF, FN, FCC, WOSJ, BBA, CEZ and AMM
 Writing of the paper: JMMLF, FCC and FN
 Critical analysis: JMMLF, FN and FCC
 Final text approval: JMMLF, FN, FCC, WOSJ, BBA, CEZ, AMM and GGC
 Statistical analysis: JMMLF and FCC
 Overall responsibility: JMMLF, FN and FCC
 Financing information: JMMLF, FN and FCC
 All authors have read and approved the final version of the paper submitted to the J Vasc Bras.