

Severe ischemia of lower limbs due to arteritis caused by HIV infection

Isquemia grave de membros inferiores por arterite por HIV

Guilherme Benjamin Brandão Pitta¹, Cezar Ronaldo Alves Silva², Josué Dantas de Medeiros², Marina Regueira Pitta³, Isabela Mariz de Lima³, Rafaela Chioquetta³, Mayra Macena Gomes⁴

Abstract

The acute limb ischemia may manifest itself, albeit unusual, as a consequence of vasculitis associated with human immunodeficiency virus (HIV). This case report described a patient seropositive for HIV who developed bilateral distal ischemia with temperature decrease of distal legs and feet, severe pain, cyanosis of fixed toes, and absence of distal pulses. She underwent treatment with thrombolytic therapy, showed signs of injury resulting from ischemia and reperfusion tissue injury with tissue loss in the distal regions of the fingers, but with improvement of the signs and symptoms of lower limbs. It is a rare case in literature due to the association of vasculitis with HIV and to the torment of distal vases of the lower limbs. Despite of that, the knowledge of the pathology is extremely important because of the repercussion in the patients' lives.

Keywords: thrombosis; vasculitis; thrombolytic therapy.

Resumo

A isquemia aguda de membros pode se manifestar, embora de forma incomum, como consequência à vasculite associada ao vírus da imunodeficiência humana (HIV). O presente caso descreve a evolução de uma paciente soropositiva para o HIV, que apresentou quadro de isquemia distal bilateral, com diminuição da temperatura de terço distal das pernas e pés, dor intensa, cianose fixa de pododátiles e ausência de pulsos distais. Submetida ao tratamento com terapia trombolítica, apresentou sinais de lesões decorrentes da isquemia e lesão tecidual de reperfusão com perda tecidual em regiões distais dos dedos, porém com melhora dos sinais e sintomas dos membros inferiores. Trata-se de um caso raro na literatura em função da associação da vasculite com o HIV e do acometimento dos vasos distais nos membros inferiores. Entretanto, o conhecimento desta associação é de extrema importância devido à repercussão na vida dos pacientes acometidos.

Palavras-chave: trombose; vasculite; terapia trombolítica.

Introduction

Acute limb ischemia is defined as any acute reduction of limb perfusion, causing potential threat to limb viability, with less than 14 days of clinical progress^{1,2}. Infection caused by the human immunodeficiency virus (HIV) may lead to vascular lesions, although this is not common. Such lesions may be a consequence of direct infection of endothelial cells by HIV or result from hypercoagulability^{3,4}.

Several types of vascular lesions have been reported, especially vasculitis⁵, which comprise a heterogeneous group

of disorders histologically characterized by the presence of inflammatory process infiltrating blood vessel walls^{6,7}. This scenario hastens the development of cardiovascular diseases⁸ and may lead to tissue ischemia or affect vessel integrity^{1,2}.

The etiology of vasculopathies associated with HIV infection has probably a multifactorial origin. For practical reasons, they were classified as vasculitis associated with HIV, atherosclerotic vascular disease related to HIV and vasculitis secondary to antiretroviral therapy or both⁹.

A wide variety of vasculitis can be associated with HIV infection, such as hypersensitivity vasculitis,

Study carried out at the Hospital Memorial Arthur Ramos – Maceió (AL), Brazil.

Presented at the V Congresso Médico da Universidade Católica de Brasília, in August 2010.

¹ Doctor Professor, Universidade de Ciências da Saúde de Alagoas; Angiologist; Vascular Surgeon, Hospital Memorial Arthur Ramos – Maceió (AL), Brazil.

² Angiologists and Vascular Surgeons, Hospital Memorial Arthur Ramos – Maceió (AL), Brazil.

³ Medical student at Universidade Católica de Brasília – Brasília (DF), Brazil.

⁴ Medical student at Universidade Federal de Alagoas – Maceió (AL), Brazil.

Financial support: none.

Conflict of interest: nothing to declare.

Submitted on: 11.08.10. Accepted on: 09.02.11.

J Vasc Bras. 2011;10(4):319-324.

leukocytoclastic vasculitis, periphlebitis retinae, eosinophilic vasculitis, Kawasaki syndrome, polyarteritis nodosa, vasculitis/perivasculitis in the retina and encephalopathy caused by HIV, cutaneous and muscular vasculitis and systemic vasculitis^{6,10}. Despite the various types of vasculitis that have been described, lesions are usually restricted to an isolated or a small number of visceral vessels and they generally affect small- and/or medium-caliber vessels^{11,12}.

It is extremely important to recognize, at the anamnesis and physical examination, the characteristics of acute arterial occlusion of the limbs to rule out differential diagnoses. Acute arterial occlusion is typically characterized by the sudden start of excruciating pain, which may have a rapid or insidious course. The pain may be associated with reduced cutaneous temperature, reduced or no pulses, cyanosis, paresthesia and paresis¹³.

The main differential diagnoses are: ischemic neuropathy; diabetic and non-diabetic sensitive neuropathy; reflex sympathetic dystrophy and atherosclerosis, when acute stenosis or arterial occlusion is present, although this is usually an uncommon presentation¹. Thromboembolectomy is still the treatment of choice to acute arterial occlusion in vessels which caliber allows the surgical access. However, thrombolysis has been proposed as a less invasive alternative, which may replace surgery in specific cases², such as when distal vessels are affected. Prospective, multicenter and randomized studies demonstrated that patients with lower limb ischemia, with a maximum of 14-day course, benefitted from thrombolytic therapy in terms of survival, limb salvage, late patency results and complementary surgery magnitude².

A possible occurrence after perfusion is restored with thrombolytic therapy of an ischemic limb is ischemia-reperfusion syndrome. It results from functional and

structural alterations that occur after the blood flow is restored, causing innumerable harmful effects, such as: necrosis of injured cells, accentuated cellular edema and uneven flow restoration^{14,15}. The tissue injuries can be reversible or irreversible, proportionally to the ischemia and hypoxia time (period from the onset of occlusion to reperfusion), to which the affected tissue was submitted¹⁶.

In this case, the type of vasculitis presented by the patient was characterized by arteritis of distal vessels, which developed into acute thrombosis of the distal arteries of lower limbs and, consequently, distal ischemia of both lower limbs.

Objective

This article consists of the case report of an acute distally located lower limbs arterial thrombosis in a female patient, HIV-seropositive, who presented with severe limb ischemia due to HIV-associated vasculitis.

Methods

A 38-year-old married female and HIV-seropositive patient, born in Maceió, in the State of Alagoas, was on antiretroviral therapy with zidovudine, lamivudine and efavirenz for about two years, with no evidence of disease activity. The patient presented bilateral distal ischemia with reduced temperature of distal third of both legs and feet, intense pain, fixed cyanosis of toes and absence of distal pulses (Figures 1 e 2).

The patient underwent lower limb angiography via antegrade femoral catheterization, using Seldinger's technique. The exam showed bilateral occlusion of the anterior and posterior tibial arteries and fibular artery, from the middle

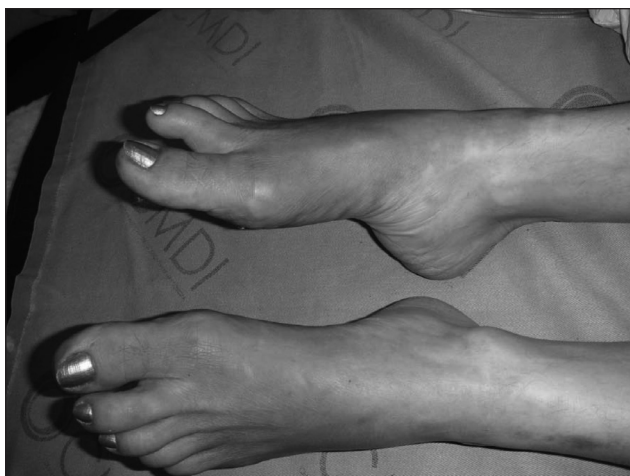

Figure 1. Erythema in the distal third of legs and feet.

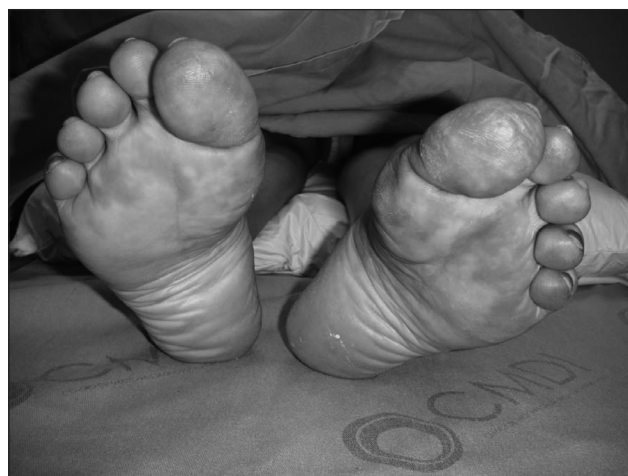

Figure 2. Cyanosis of toes and erythrocyanosis in the plantar area of feet.

third of the legs to the feet (Figures 3 to 5). Thrombolytic therapy with 50 mg alteplase was carried out for three days. On the first day, 10 mg of alteplase was diluted in 100 mL of glucose solution and administered as an intra-arterial bolus. The remaining 40 mg were diluted in 200 mL of glucose solution and were administered throughout the next 24 hours. The following two days 50 mg of alteplase, diluted in 200 mL of glucose solution, were administered daily. The fibrinolytic therapy was monitored through plasma fibrinogen level monitoring every eight hours.

In addition, intravenous therapy was initiated with 50 mg hydrocortisone every 12 hours, for ten days, to treat the vasculitis.

Bilateral lower limb angiography for post-thrombolytic therapy control showed improved perfusion and revascularization of the distal third of both lower limbs and feet

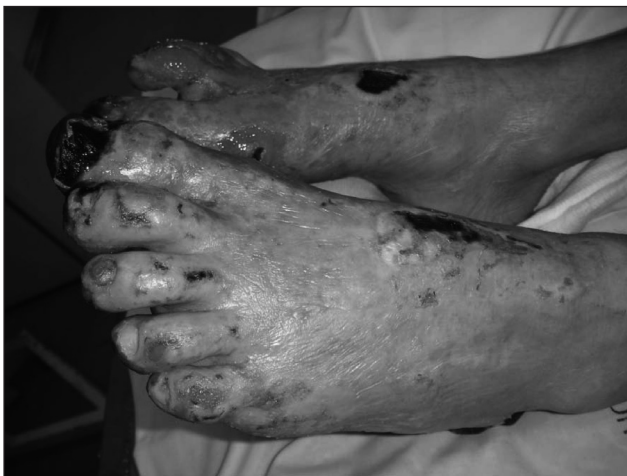

Figure 3. Angiography for pre-thrombolytic control showing absence of blood flow in the distal third of left leg and foot.

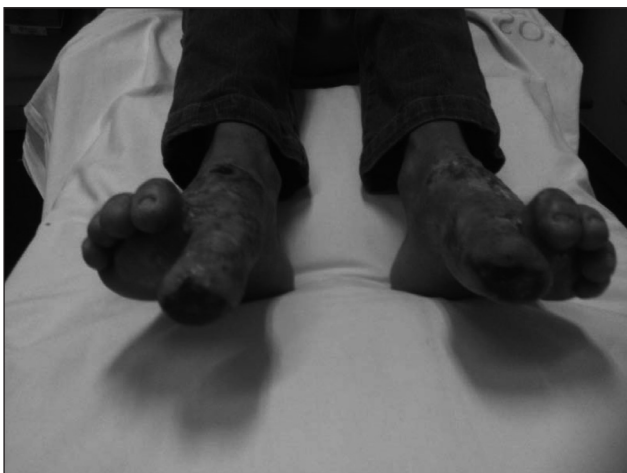

Figure 4. Angiography for pre-thrombolytic control showing absence of blood flow in the distal third of right leg and foot.

(Figures 6 to 8). She developed necrosis and phlyctenas of both halluces (Figure 9). However, the patient presented improvement of the pain, cyanosis and low temperature of the limbs and delimitation of the areas of necrosis. Then, she was given 20 µcg of alprostadil (PGE1), diluted in 100 mL of saline solution, every 12 hours, using an infusion pump, and 60 mg of subcutaneous enoxaparin sodium every 12 hours. Both were started on day 3 of treatment, after thrombolytic therapy had been discontinued and kept until discharge from hospital.

At the end of treatment, salvage of affected limbs occurred, with the ischemic condition resolved and reperfusion of both lower limbs. A limited debridement of the digital pulps of halluces was necessary (Figures 10 and 11).

Results

The patient progressed from the initial clinical presentation, with pain relief and improvement of the fixed cyanosis of toes, reduced temperature of limbs and absence of pulses. After starting the treatment, revascularization and reperfusion of the distal third of the legs and feet were observed and, consequently, recovery of the affected limbs.

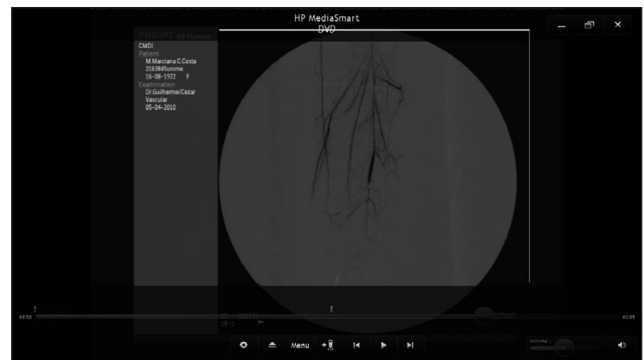

Figure 5. Angiography for pre-thrombolytic control showing absence of blood flow in the distal third of right leg and foot.

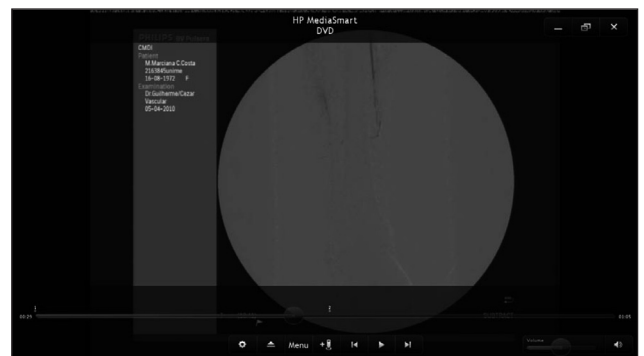


Figure 6. Angiography for pre-thrombolytic control showing revascularization of the distal third of left leg and foot.

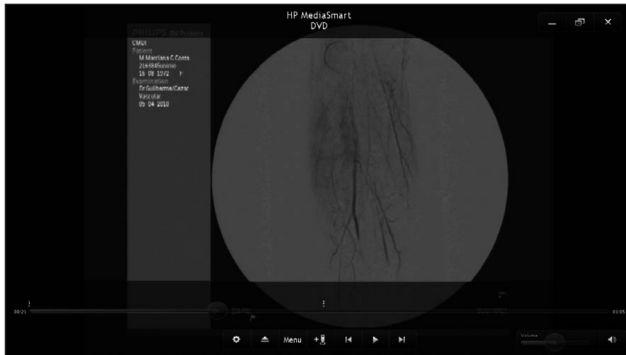


Figure 7. Angiography for pre-thrombolytic control showing revascularization of the distal third of right leg and foot.

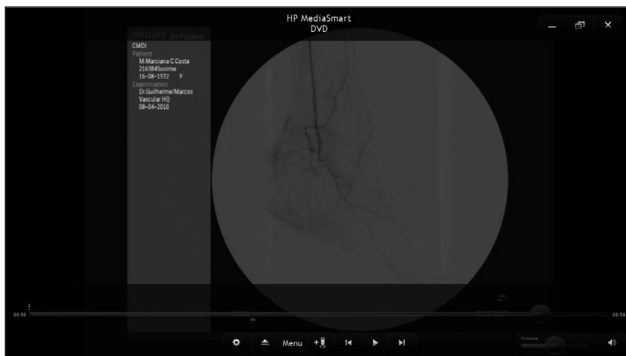


Figure 8. Angiography for pre-thrombolytic control showing revascularization of the distal third of right leg and foot.

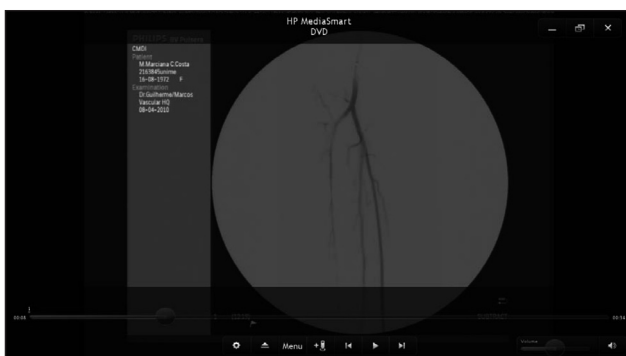

Figure 9. Necrosis of hallux and phlyctenas occurring bilaterally as a result of post-thrombolysis ischemia and reperfusion injury.

Discussion

The symptoms presented by the patient can be explained by reduced arterial blood flow in the distal third of lower limbs, due to acute arterial occlusion caused by thrombus, secondary to HIV-associated arteritis.

The antiretroviral therapy has changed the natural history of HIV infection over the years, as well as the

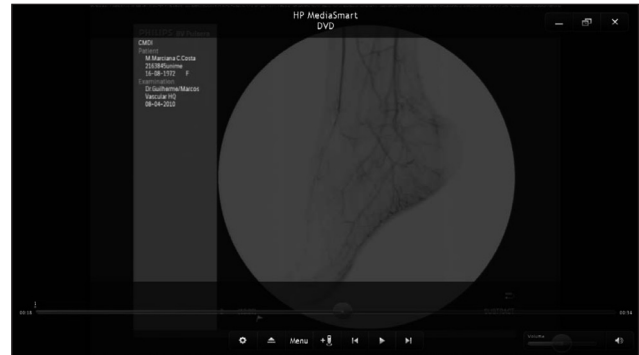

Figure 10. Salvage of lower limbs and debridement of distal extremities of halluces.

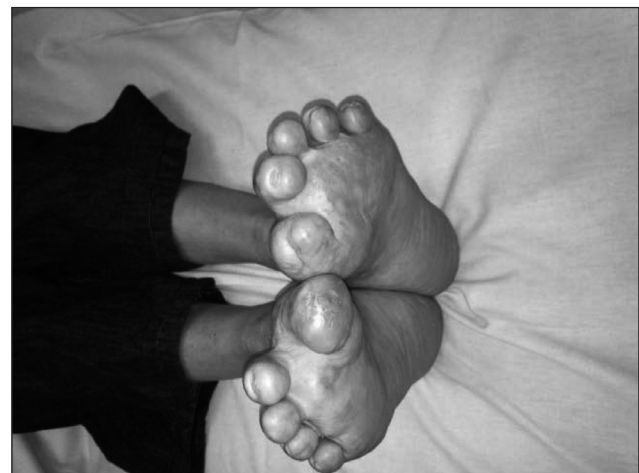


Figure 11. Salvage of lower limbs, after three months of treatment.

frequency and expression of several related clinical syndromes. Furthermore, antiretroviral therapy is directly associated with drug toxicity and indirectly associated with the immune system reconstruction, and the development of new syndromes, as the HIV infection causes imbalance in the immune system, characterized by immunosuppression and hyperactivity. Such alterations of the immune system may lead to reduced self-tolerance and eventually to the development of autoimmunity¹⁷. Antiretroviral therapy can be regarded as one of the causes of vasculitis in small- and medium-caliber vessels. The drugs suggested as possible inducers include abacavir, nevirapine, efavirenz, trimethopim/sulfamethoxazole, among others⁹. It is not possible to determine whether there was any influence of the drugs being used in the reported case, but a possible interaction of this factor in the development of acute arterial occlusion in the patient can not be ruled out.

The intra-arterial thrombolysis used in the patient's treatment is the therapy of choice when small-caliber distal

vessels are affected, as it allows the drug to reach the injury site in a more effective and faster manner than thromboembolectomy, and it can ensure unclogging of the main arteries, as well as smaller distal vessels². The treatment efficacy could be demonstrated by proper blood perfusion of the affected limbs.

The treatment of vasculitis is essentially based on the combined administration of corticosteroids with cytotoxic drugs (cyclophosphamide is the most frequently used)¹⁸. Corticotherapy with hydrocortisone was necessary in the treatment of this type of vasculitis to control or to induce remission of the disease and to prevent relapses, minimizing sequelae¹⁹. The drug selection was an indication of the Infectology team. Cyclophosphamide was not used, because the patient was already taking immunosuppressors for the HIV treatment.

Alprostadil is a compound made from naturally occurring fatty acids, with several pharmacological effects, such as vasodilation and platelet aggregation inhibition²⁰. The use of this drug was essential for the patient's progress, as it antagonizes the formation of new thrombi and, consequently, prevents possible arterial occlusion in other areas. Necrosis of the digital pulps of halluces and the occurrence of phlyctenas resulted from the ischemia-reperfusion syndrome, which appeared after limb revascularization¹⁴⁻¹⁶.

In principle, the presence of thrombophilia markers influence the decision to prevent new thrombotic events (secondary prophylaxis) and may help to decide on duration and intensity of therapy²¹. However, the investigation of thrombophilia markers was not required for this patient, since it is not a routine practice for patients taking anticoagulants, and the detection of such markers does not influence the treatment of an acute event, because the treatment of thrombosis is not dependent on its cause.

Conclusion

HIV infection presents various interaction with the affected patient's health. This case report demonstrates the importance of having broad and proper perception regarding the possible associated conditions that may occur as a result of this disease. Vasculitis associated with HIV are rare, but cause an important repercussion on the patient's life, due to their possible complications and future impairments. Based on that, it concludes that an aggressive and adequate treatment is essential for the remission of situations that arise in this context and to ensure the patient's quality of life.

References

1. Baptista-Silva JCC. Isquemia Crônica Crítica de Membro: Diagnóstico Clínico. In: Pitta GBB, Castro AA, Burihan E, editores. *Angiologia e cirurgia vascular: guia ilustrado*. Maceió: UNCISAL/ECMAL & LAVA; 2003.
2. Rossi FH, Izukawa NM, Oliveira LAV, Silva DG. O valor atual da trombólise na oclusão arterial aguda do membro inferior. *J Vasc Br*. 2003;2(2):129-40.
3. Cotter BR, Andrade ACO. Endothelial Function and Cardiovascular Diseases in HIV Infected Patient. *BJID*. 2006;10(2):139-45.
4. Bush RL, Bianco CC, Bixler TJ, Lin PH, Lumsden AB. Spontaneous arterial thrombosis in a patient with HIV infection – successful treatment with pharmacomechanical thrombectomy. *J Vasc Surg*. 2003;38(2):392-5.
5. Loire R, Capron L. Complications vasculaires del infection par Le VIH. *Sang Thrombose Vaisseaux*. 1995;7(7):487-92.
6. Bozza A, Levy R. Vasculites. In: Pitta GBB, Castro AA, Burihan E, editores. *Angiologia e cirurgia vascular: guia ilustrado*. Maceió: UNCISAL/ECMAL & LAVA; 2003.
7. Ramaprasad C, Pitrak D. Infections of the peripheral arterial system. In: Dieter RS, Dieter RAJr, Dieter RAlll. *Peripheral arterial disease*. Nova York: McGraw Hill Professional; 2008. p. 157-68.
8. Chi D, Henry J, Kelley J, Thorpe R, Smith JK, Krishnaswamy G. The effects of HIV infections on endothelium function. *Endothelium*. 2000;7(4):223-42.
9. Naidoo NG, Beninfield SJ. Other manifestations of HIV vasculopathy. *Sajs*. 2009;47(2):46-53.
10. Cossermelli W. Vasculites. In: *Vasculites associadas às infecções*. São Paulo: Fundação para o desenvolvimento da Reumatologia; 2002. p. 135-48.
11. Chetty R. Vasculitides associated with HIV infection. *J Clin Pathol*. 2001;54(4):275-8.
12. Staub HL. Vasculites imunológicas – diagnóstico e diagnóstico diferencial. *Tem Reumatol Clin*. 2008;9(3):72-6.
13. Pereira DAG, Custódio MX, Carvalho JPF, Carvalho AMB, Cunha-Filho IT. Avaliação e tratamento fisioterápico na doença arterial obstrutiva periférica de membro superior: um estudo de caso. *J Vasc Br*. 2008;7(1):72-5.
14. Bitu-Moreno J, Francischetti I, Hafner L. Lesões de isquemia-reperusão em músculos esqueléticos: fisiopatologia e novas tendências de tratamento, com ênfase em reperusão controlada. *J Vasc Br*. 2002;1(2):113-20.
15. Brasileiro JL, Fagundes DJ, Mijji LON, Oshima CTF, Teruya R, Marks G, et al. MA. Isquemia e reperusão de músculo sóleo de ratos sob ação da pentoxifilina. *J Vasc Br*. 2007;6(1):50-63.
16. Campos EBP, Yoshida WB. O papel dos radicais livres na fisiopatologia da isquemia e reperusão em retalhos cutâneos: modelos experimentais e estratégias de tratamento. *J Vasc Br*. 2004;3(4):357-66.
17. Macedo CG, Panato CS, Borjaille BP, Antônio SF. Manifestações reumatológicas e auto-imunes em pacientes. *Rev Bras Med*. 2006;7(2):71-7.
18. Barros MT, Barros RT. Vasculites: classificação, patogênese e tratamento. *Rev Bras Alerg Imunopatol*. 1998;21(4):128-38.

19. Guillevin L, Dörner T. Vasculitis: mechanisms involved and clinical manifestations. *Arthritis Res Ther.* 2007;9(Suppl 2):S9.
20. Araújo M. Farmacoterapia nas doenças vasculares periféricas. In: Pitta GBB, Castro AA, Burihan E, editores. *Angiologia e cirurgia vascular: guia ilustrado.* Maceió: UNCISAL/ECMAL & LAVA; 2003. pt.13, cap.74. Disponível em: http://www.lava.med.br/livro/pdf/marcelo_farmacoterapia.pdf.
21. Tripodi A, Mannacci PM. Laboratory investigation of thrombophilia. *Clin Chem.* 2001;47(9):1597-606.

Correspondence

Marina Regueira Pitta
CCSW 02, Lote 1 – Bloco 2 – Apto. 210
CEP 70680-250 – Brasília (DF), Brazil
E-mail: marina_pitta@hotmail.com

Author's contributions

Conception and design: GBBP
Analysis and interpretation: GBBP, MRP, MMG
Data collection: MRP, MMG
Writing the article: MRP, MMG, IML, RC
Critical revision of the article: GBBP
Final approval of the article*: GBBP, CRAS, JMD, MRP, IML, RC E MMG
Statistical analysis: N/A
Overall responsibility: GBBP, JMD E CRAS

*All authors have read and approved the final version submitted at the J Vasc Bras.