

CASE REPORT

Treatment of hemodialysis access steal syndrome by distal revascularization arterial ligation: report of three cases

Tratamento da síndrome de roubo de fístula arteriovenosa pela técnica de revascularização distal e ligadura arterial: relato de três casos

Afonso César Polimanti¹, Sidnei José Galego², Rafael Vilhena de Carvalho Fürst¹, Gabriela da Silveira Moraes³, Rafael Camacho da Silva Barbosa³, Sônia Regina Silveira⁴, Maria do Carmo Silva Neves Kawhage⁴, João Antônio Correia⁵

Abstract

Arteriovenous fistulas for hemodialysis may present long-term complications. Among the least frequent complications, there is the steal syndrome. The authors report the experience of three patients that presented with critical limb ischemia years after the access confection of brachiocephalic arteriovenous fistulas, with little response to clinical treatment. Distal revascularization interval ligation was performed in all cases, with good outcome. Due to small quantity of the cases, we decided to report the experience and review the literature on the subject.

Keywords: arteriovenous shunt; ischemia; hemodialysis; arteriovenous fistula; therapeutic.

Resumo

Fístulas arteriovenosas para hemodiálise podem apresentar complicações a longo prazo. Entre as complicações mais raras, há a isquemia distal por síndrome de roubo. Os autores relataram a experiência de três casos de pacientes portadores de fístulas braquiocéfálicas, em funcionamento por longo prazo e que evoluíram com isquemia crítica do membro, sem resposta com tratamento clínico. Com o intuito de tratar esta afecção e preservar o acesso vascular, optou-se pela realização da revascularização distal interposta por ligadura arterial. Devido à raridade dos casos, relatou-se a experiência e apresentou-se uma revisão de literatura.

Palavras-chave: derivação arteriovenosa cirúrgica; isquemia; hemodiálise; fístula arteriovenosa; terapêutica.

Introduction

The prevalence of patients with chronic renal disease in need of dialysis is high. In Brazil, it is estimated that there are over 77,500 patients in dialysis¹. Hemodialysis is the best tolerated method of dialysis, but it requires a functional vascular access^{1,2}. Arteriovenous fistula (AVF) is the best vascular access for this purpose, for it results in fewer complications and allows long-term treatment, thus increasing patients' survival rate².

The most common complications of AVF are: thrombosis, infection, pseudoaneurysm, and, less frequently, distal ischemia³. The latter presents a typical clinical picture called steal syndrome, which may result in limb loss in severe cases⁴.

The most common treatment is AVF ligation aiming at restoration of distal blood flow⁵. This procedure makes the vascular access unviable, so the surgeon must search for another one, which may be difficult sometimes. An alternative, still little used in Brazil, is distal

Study carried out at the Angiology and Vascular Surgery discipline of the Faculdade de Medicina do ABC (FMABC) – Santo André (SP), Brazil.

¹ Assistant physicians of Angiology and Vascular Surgery at FMABC – Santo André (SP), Brazil.

² Post-doctorate degree of Angiology and Vascular Surgery at FMABC – Santo André (SP), Brazil.

³ Medical students at FMABC – Santo André (SP), Brazil.

⁴ Coordinators of Centro Integrado de Nefrologia de São Caetano do Sul (CINSCS) – São Caetano do Sul (SP), Brazil.

⁵ Professor of Angiology and Vascular Surgery at FMABC – Santo André (SP), Brazil.

Financial support: none.

Conflict of interest: nothing to declare.

Submitted on: 07.24.11. Accepted on: 01.11.12.

J Vasc Bras. 2012;11(2):158-161.

revascularization interval ligation (DRIL)⁶⁻⁸. This procedure is an alternative to simple ligation that, besides treating the ischemia, preserves the access and assures the continuation of dialysis⁵.

In this paper, we report three cases of critical limb ischemia due to steal syndrome, treated by DRIL, and review the literature on the subject.

Case Description

Case 1: the patient was a 67-year-old male presenting diabetes and chronic renal failure due to diabetic nephrosclerosis requiring dialysis. He had a left brachiocephalic fistula confection four years earlier and developed arm claudication in late postoperative period, thus requiring assistance to perform housekeeping tasks and presenting rest pain during dialysis. On physical examination: normal left axillary and brachial pulses; absence of distal pulses; bruits and thrill along the cephalic vein, from the antecubital crease to the deltopectoral groove, with a matured vein; alterations in hair growth and limb atrophy distal to the AVF associated with temperature gradient on the distal third of the hand and forearm. Doppler ultrasonography showed biphasic flow in the axillary-brachial artery with flow inversion distally to the arteriovenous anastomosis. Radial and ulnar arteries with low flow and monophasic pattern of low resistance, suggesting distal ischemia. Monophasic and low-resistance flow, and high flow on the arm cephalic vein not suggestive of stenosis.

Case 2: the patient was a 62-year-old male with diabetes, hypertension, and chronic renal failure due to nephrosclerosis requiring dialysis, He had a left brachiocephalic fistula performed eight years earlier and had developed rest pain in the forearm and hand during dialysis. Clinical and imaging findings were similar to those of case 1.

Case 3: patient was a 74-year-old male with hypertension and chronic renal failure due to hypertensive nephrosclerosis. Two years earlier he had a brachiocephalic fistula performed at the left upper extremity and had developed arm claudication and rest pain during dialysis sessions in the last three months.

In all cases, initial clinical treatment was exercises of the affected limb, antiplatelet agent and statin administration, showing no significant improvement.

Failure of medical treatment led to the decision of treating the patients with DRIL. In cases 1 and 2, the

upper arm basilic vein was used as a graft between the brachial artery proximal to the AVF and the distal brachial artery at its bifurcation.

In case 3, the basilic vein was found to have signs of phlebitis and occlusion in its proximal portion at operation, which precluded its use as arterial graft. A segment of the greater saphenous vein of the right thigh was used as a graft. This patient had the arteriovenous anastomosis right at the brachial artery bifurcation, which led to change the surgical approach. The proximal anastomosis was performed at the brachial artery. The distal anastomosis was performed at the proximal radial artery, which was ligated between its origin, at the brachial artery bifurcation, and the distal anastomosis, as shown in Figure 1. The radial artery was chosen because of its superficial location and little repercussion of the ligation in hand perfusion as compared to the ulnar artery.

The patients had an uneventful recovery. Follow-up lasted six months, and the grafts and hemodialysis accesses were all patent.

Discussion

Physiological flow reversal after performing an AVF is common⁹. Symptoms of ischemia are rare and usually relieved by physiologic distal vasodilation¹⁰. The ischemic symptoms may be caused by the severity of atherosclerotic disease distal to the arteriovenous anastomosis⁹.

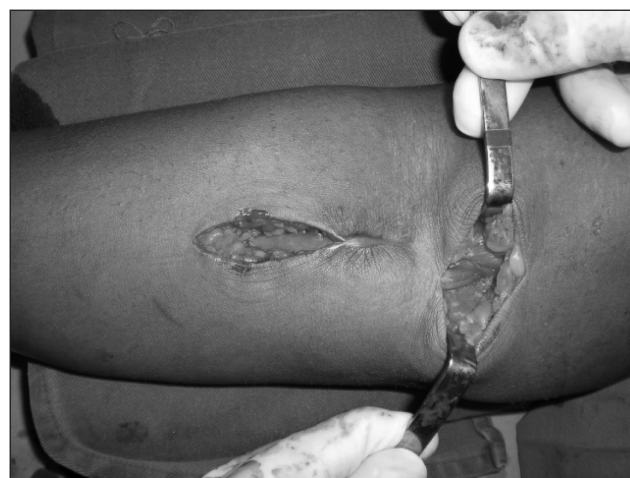

Figure 1. Surgical procedure in patient 1 showing brachiocephalic graft from the greater saphenous vein, and ligation of the brachial artery distally to the arteriovenous anastomosis.

The diagnosis is based on the clinical presentation: a pale and cold extremity, with weak pulses distal to the access, limb claudication, possibly paresthesia and trophic lesions¹¹. A drop in wrist-brachial index (WBI) may be detected at Doppler ultrasonography. A WBI under 0.57 is related to symptomatic ischemia of the upper limb^{9,12}.

There are also reports of steal syndrome in lower limbs AV fistulas in the literature. Malgor et al. reported this event in the early postoperative period of a straight and synthetic AVF on the right lower limb, with clinical signs such as coldness, recently onset of claudication and significant drop in the ankle-brachial index (ABI), similar to those reported in cases of the upper limbs. The patient was submitted to DRIL, the symptoms disappeared and the access was maintained¹³.

The patient may occasionally present paresthesia distal to the anastomosis due to flow decrease of the *vasa nervorum*, a symptom that tends to be limited⁴. Electrophysiological studies allowed differential diagnosis with similar diseases such as the carpal tunnel syndrome^{14,15}.

Doppler ultrasonography is able to identify the cause of ischemia by showing flow inversion in the brachial artery distal to the anastomosis, and reduced flow in the distal arteries of the forearm. It is important for surgical planning to show the distal arterial outflow and the assessment of palmar arch patency¹⁶⁻¹⁸.

Many techniques for the treatment of ischemic syndrome in patients with upper fistulas have been described, and they aim to decrease the AVF flow, thus improving distal ischemia and decreasing flow inversion in the distal artery^{8,19-21}.

One approach is to perform plicature by a longitudinal suture of the venous segment right after the arteriovenous anastomosis, reducing its diameter and, therefore its flow, as shown in Figure 2A. This technique usually causes a significant hemodynamic stenosis and the rate of AVF thrombosis at follow-up is high¹⁹.

DRIL consists of a bypass from the brachial artery to an artery distal to the AV anastomosis, followed by ligation of the artery between the AV fistula and the distal anastomosis, as shown in Figure 2B. This technique results in a high rate of clinical improvement, but the handicap of distal limb perfusion depending exclusively on the bypass graft's patency, for the native artery is ligated during the procedure⁸.

Another technique described in the literature is treating the steal syndrome by directing flow to the distal arteries. A bypass is performed from the arterialized vein proximal to the anastomosis, to the radial artery on

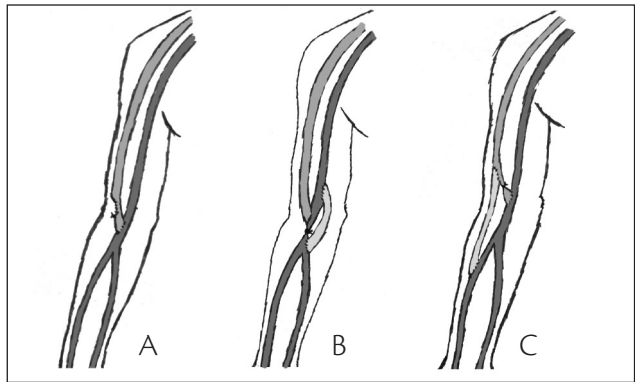


Figure 2. Surgical methods for steal syndrome correction. A: plicature; B: distal revascularization interval ligation (DRIL); C: derivation of the arterialized vein to the radial artery.

the proximal third of the forearm, and then the ligation of the arterialized vein close to the anastomosis is performed, as shown in Figure 2C. This technique allows limb revascularization with no need for ligation of the native artery. It tends to reduce the fistula flow, but long-term follow-up has not been reported yet²⁰.

When all technical options have been exhausted or limb revascularization is impeded due to extensive calcification, fistula ligation may resolve the ischemic symptoms and a new vascular access may be required²¹.

Conclusion

Symptomatic AV fistula-related steal syndrome is a rare entity that can be treated with the preservation of hemodialysis accesses.

References

1. Sesso Rde C, Lopes AA, Thome FS, Lugon JR, Burdmann EA. Brazilian dialysis census, 2009. *J Bras Nefrol.* 2010;32:374-8.
2. Anel RL, Yevzlin AS, Ivanovich P. Vascular access and patient outcomes in hemodialysis: questions answered in recent literature. *Artif Organs.* 2003;27:237-41.
3. Yiltok SJ, Orkar KS, Agaba EI, et al. Arteriovenous fistula for patients on long term haemodialysis in jos, Nigeria. *Niger Postgrad Med J.* 2005;12:6-9.
4. Lazarides MK, Stamos DN, Kopadis G, Maltezos C, Tzilalis VD, Georgiadis GS. Onset of arterial 'steal' following proximal angioaccess: immediate and delayed types. *Nephrol Dial Transplant.* 2003;18:2387-90.
5. Mickley V. Steal syndrome--strategies to preserve vascular access and extremity. *Nephrol Dial Transplant.* 2008;23:19-24.
6. Katz S, Kohl RD. The treatment of hand ischemia by arterial ligation and upper extremity bypass after angioaccess surgery. *J Am Coll Surg.* 1996;183:239-42.

7. Knox RC, Berman SS, Hughes JD, Gentile AT, Mills JL. Distal revascularization-interval ligation: a durable and effective treatment for ischemic steal syndrome after hemodialysis access. *J Vasc Surg.* 2002;36:250-5.
8. Linardi F, Linardi FF, Bevilacqua JL, Morad JFM, Costa JA. Tratamento cirúrgico da "síndrome do roubo" em acesso vascular para hemodiálise com revascularização distal e ligadura arterial. *J Vasc Bras.* 2006;5:117-22.
9. Yu SH, Cook PR, Canty TG, McGinn RF, Taft PM, Hye RJ. Hemodialysis-related steal syndrome: predictive factors and response to treatment with the distal revascularization-interval ligation procedure. *Ann Vasc Surg.* 2008;22:210-4.
10. Galego SJ, Goldenberg S, Ortiz JP, De Oliveira Gomes P, Ramacciotti E. Comparative blood flow study of arteriovenous fistulae in canine femoral arteries: modified latero-lateral and end-lateral techniques. *Artif Organs.* 2000;24:235-40.
11. Malik J, Tuka V, Kasalova Z, et al. Understanding the dialysis access steal syndrome. A review of the etiologies, diagnosis, prevention and treatment strategies. *J Vasc Access.* 2008;9:155-66.
12. Goff CD, Sato DT, Bloch PH, et al. Steal syndrome complicating hemodialysis access procedures: can it be predicted? *Ann Vasc Surg.* 2000;14:138-44.
13. Malgor RD, Yoshida RdA, Sobreira ML, Giannini Mn, Yoshida WB, Rollo HA. Tratamento da síndrome do roubo devido a fistula arteriovenosa para hemodiálise em membro inferior por meio da técnica de ligadura arterial e revascularização distal (técnica de DRIL). *J Vasc Bras.* 2007;6:288-92.
14. Kirksey L. Ischemic monomelic neuropathy: an underappreciated cause of pain and disability following vascular access surgery. *J Vasc Access.* 2010;11:165-8.
15. Zamora JL, Rose JE, Rosario V, Noon GP. Hemodialysis-associated carpal tunnel syndrome. A clinical review. *Nephron.* 1985;41:70-4.
16. Wixon CL, Hughes JD, Mills JL. Understanding strategies for the treatment of ischemic steal syndrome after hemodialysis access. *J Am Coll Surg.* 2000;191:301-10.
17. Wilson SW, Pollard RE, Lees VC. Management of carpal tunnel syndrome in renal dialysis patients using an extended carpal tunnel release procedure. *J Plast Reconstr Aesthet Surg.* 2008;61:1090-4.
18. Zamani P, Kaufman J, Kinlay S. Ischemic steal syndrome following arm arteriovenous fistula for hemodialysis. *Vasc Med.* 2009;14:371-6.
19. Jackson KL, Charpentier KP. Quantitative banding for steal syndrome secondary to arteriovenous fistulae. *Ann R Coll Surg Engl.* 2010;92:534.
20. Callaghan CJ, Mallik M, Sivaprakasam R, Iype S, Pettigrew GJ. Treatment of dialysis access-associated steal syndrome with the "revision using distal inflow" technique. *J Vasc Access.* 2011;12:52-6.
21. Gupta N, Yuo TH, Konig G 4th, et al. Treatment strategies of arterial steal after arteriovenous access. *J Vasc Surg.* 2011;54:162-7.

Correspondence

Afonso César Polimanti
 Rua Itapeva, 518 – cj. 509/510 – Bela Vista
 CEP 01332-000 – São Paulo (SP), Brazil
 E-mail: afonso_sp@yahoo.com.br

Authors' contributions

Conception and design: ACP, RVCF, GSM, RCSB
 Analysis and interpretation: ACP, SJG, RVCF, GSM, RCSB, SRS, MSCSNK
 Data collection: ACP, RVCF, GSM, RCSB
 Writing the article: ACP, SJG, RVCF, GSM, RCSB, SRS, MSCSNK, JAC
 Critical revision of the article: ACP, SJG, RVCF, SRS, MSCSNK, JAC
 Final approval of the article*: ACP, SJG, RVCF, GSM, RCSB, SRS, MSCSNK, JAC
 Statistical analysis: ACP, RVCF
 Overall responsibility: ACP, SJG, RVCF, SRS, MSCSNK, JAC
 *All authors have read and approved the final version submitted to *J Vasc Bras.*